

REFRACTORY ONYCHOMYCOSIS DUE TO TRICHOPHYTON RUBRUM: COMBINATION THERAPY WITH ITRACONAZOLE AND TERBINAFAINE

OPORNA NA LECZENIE GRZYBICA PAZNOKCI WYWOŁANA PRZEZ TRICHOPHYTON RUBRUM: KOMBINOWANA TERAPIA ITRAKONAZOLEM I TERBINAFINĄ

Bonifaz Alexandro, Vázquez-González Denisse, Saúl Amado, Fierro-Arias Leonel, Ponce-Olivera M. Rosa

*Dermatology Service & Mycology Department, General Hospital of Mexico OD.
a bonifaz@yahoo.com.mx*

N Dermatol Online. 2011; 3(2): 108-112

Date of submission: 06.03.2011 / acceptance: 20.04.2011

Conflicts of interest: None

Abstract

Objectives: Evaluate the efficacy and tolerability of itraconazole plus terbinafine for refractory onychomycosis. This is a prospective clinical trial. Patients with proven *Trichophyton rubrum* onychomycosis of toenails were enrolled; the treatment consisted of weekly administration: itraconazole 200mg/day and terbinafine 250mg/day, for four months. **Results:** Thirty-two patients with onychomycosis were studied. Twenty-eight cases had distal subungual onychomycosis and 4 total dystrophic onychomycosis. At the end of the follow-up 17/32 patients had clinical and mycologic cure (53.12%), 5 had clinical improvement only (15.6%), and 10 (31.2%) failed.

Conclusion: Weekly alternate therapy with itraconazole + terbinafine represents a safe rescue treatment.

Streszczenie

Cel: Ocena skuteczności i tolerancji itraconazolu plus terbinafiny w opornej na leczenie grzybicy paznokci. Jest to prospektywne badanie kliniczne. Pacjentów z potwierdzoną grzybicą paznokci wywołaną przez *Trichophyton rubrum* zakwalifikowano do badania; leczenie polegało na cotygodniowym przyjmowaniu: itraconazol 200 mg/dobę i terbinafiny 250mg/dobę, przez cztery miesiące.

Wyniki: Przebadano trzydziestu dwóch pacjentów z grzybicą paznokci. Dwadzieścia osiem przypadków miało dystalną podpaznokciową grzybicę paznokci, a czterech całkowicie dystroficzną grzybicę paznokci. Pod koniec obserwacji 17/32 pacjentów było wyleczonych klinicznie i mykologicznie (53,12%), u 5 uzyskano tylko poprawę stanu klinicznego (15,6%), a u 10 (31,2%) leczenie nie powiodło się. **Wnioski:** Cotygodniowa zastępcza terapia itraconazol + terbinafina stanowi bezpieczną metodę leczenia w takich przypadkach.

Key words: onychomycosis; refractory; distal subungual onychomycosis; itraconazole; terbinafine; *Trichophyton rubrum*

Słowa kluczowe: grzybica paznokci; oporność na leczenie; dystalna podpaznokciowa grzybica paznokci; itraconazol; terbinafina; *Trichophyton rubrum*

Introduction

Onychomycosis is the most frequent nail disorder. Its etiology includes three agents: dermatophytes, yeasts and molds. Dermatophytic onychomycosis is the most frequent type and is caused by *Trichophyton rubrum*. Most cases occur in the toe nails and are seen more frequently in adults [1-4].

The treatment of onychomycoses has experienced changes in the past fifteen years as a result of the development of new oral antifungals, particularly the triazole derivative itraconazole and the allylamine terbinafine[5,6]. Overall, both treatments result in high cure rates and, although figures are variable,

effectiveness does not exceed 80% at the one year follow-up [7]. Nevertheless in meta-analysis studies, terbinafine proved to be superior to itraconazole in efficacy, safety and drug interactions.8-10 Both are the most widely used agents for the treatment of dermatophytic onychomycosis; itraconazole is administered continuously or as pulses, and terbinafine is given continuously [7]. Approximately 20-25% of the patients do not respond to initial therapy and they frequently switch to a different treatment. An undetermined percent do not respond to any of the therapies and this may be due to various factors [11].

In a recent paper Gupta et al. [12] report the use of the itraconazole and terbinafine combination administered alternately and combined in patients with chromoblastomycosis refractory to various treatments. Despite the small number of patients in the series, important improvement and cure were observed with the two-drug combination. The response might be due to a synergistic effect of the two drugs; we have also tried the combination successfully. Based on the former findings, this study enrolled patients with dermatophytic onychomycosis that had been refractory to both medications given at the right dose and dosing schedule, this time using an alternate weekly treatment regimen consisting of itraconazole and terbinafine.

Material and methods

This is a prospective, linear clinical trial that enrolled patients with clinically and mycologically proven dermatophyte-related onychomycosis of toenails. The patients included in the study were of both sexes, 18 years of age and older, all of them signed a consenting form to go in to the trial; all patients had received previously treatment against onychomycosis and never achieved cure (clinical and mycologic). All of them had previously been refractory to treatment with itraconazole and terbinafine given at the right doses and dosing schedules; itraconazole as 3 or more pulses (400 mg/day for one week) and terbinafine as continuous therapy for 3 or more months (250 mg/day).

This means that patients had received both treatments during different periods and did not experience neither clinical nor mycologic changes. The watch out time period with both therapy schemes was about 9 months after the last dose, because this is the minimum time period to observe the action of both antifungal agents.

Patients with immunosuppressive conditions or state were excluded, same as patients with other onychodystrophy-related disorders (psoriasis). Mycologic tests were performed consisting of KOH direct exam and culture in Sabouraud dextrose agar and Sabouraud dextrose agar with antibiotics (Mycobiotic). Only patients with a positive KOH and isolation of the causative agent were included in the study.

The treatment regimen consisted in terbinafine and itraconazole administered in alternate weeks. This means that terbinafine 250mg/day was administered after lunch for one week, followed by itraconazole 200mg/day after lunch in the following week, during the 4 months of treatment (Fig 1).

Each of the patients underwent a complete blood count and liver function tests (alkaline phosphatase, lactic dehydrogenase and transaminases, TGO and TGP) at the onset, at two months and at the end of the treatment. Clinical follow-up visits took place every two months and a final follow-up visit was scheduled for ten months after the last drug administration, i.e., one year and two months after the onset of the study.

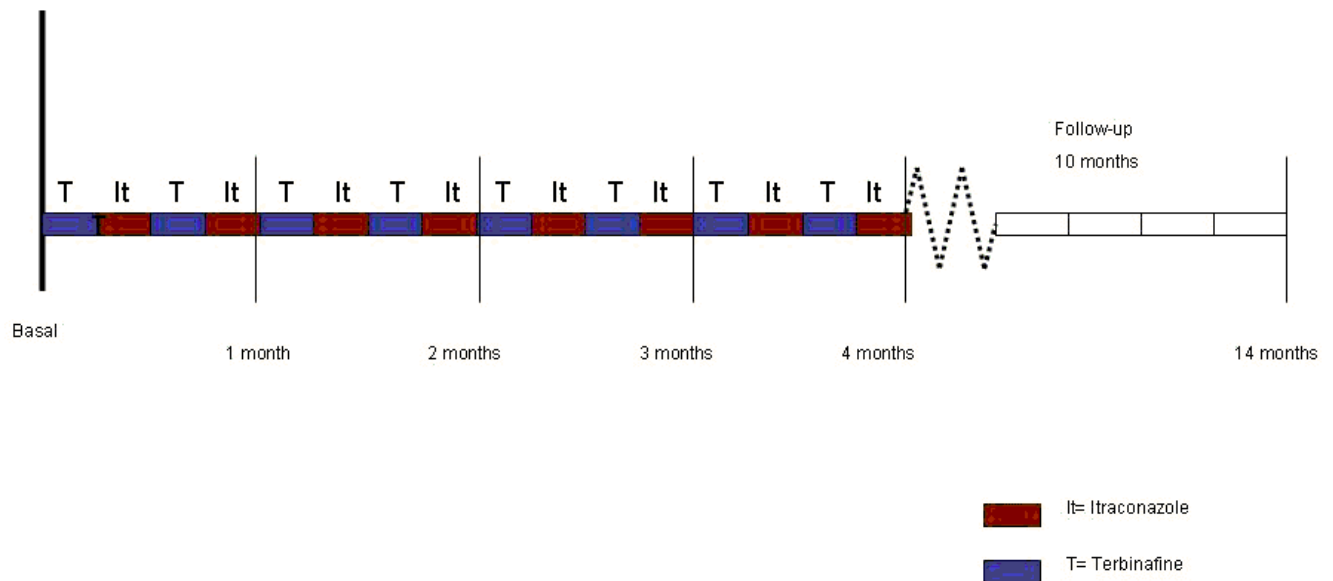


Figure 1. Scheme of treatment regimen

Results

We included 40 patients that fulfill the selection criteria, 8 patients were excluded of the study due to the lack of compliance to the therapy during the follow-up time period. Thirty-two patients who met the inclusion criteria and who had previously failed both treatments (itraconazole and terbinafine) were enrolled in this study, during 2 years and two months period (between August 2006 and September 2008). Figure 1 shows the patients'

treatment regimen. The 32 patients comprised 18 females and 14 males; the youngest patient was 32 years old and the oldest 68; mean age was 45.6 years. The minimal period of wait after the last medication was 9 months and the maximal was 1.5 years, with 11.5 months average. Clinically, 28 (87.5%) patients had distal subungual onychomycosis (DSO), and 4 (12.5%) had total dystrophic onychomycosis (TDO). In all patients the

direct exam showed filaments and the causative agent isolated in all cases was *Trichophyton rubrum*. One case had a mixture: *T. rubrum* plus *Candida parapsilosis*.

At the end of the follow-up (10 months after the last drug administration), 17 patients (53.12%) had clinical and mycologic cure, 15 of them had DSO and 2 TDO; 5 patients (15.62%) had only clinical improvement, all of them with DSO, and 10 patients failure (31.25%) did not have neither clinical nor mycologic improvement, 8 of them had DSO and 2 TDO. Concerning patients with diabetes mellitus, 3 attained cure (clinical and mycologic) and 2 failed (Fig 2).

No changes in the blood count and the liver function tests were seen during the trial. Two patients reported side effects (6.25%), one of them had mild headache that lasted two days and the other one had moderate dysgeusia for 7 days. None of them warranted stopping the treatment.

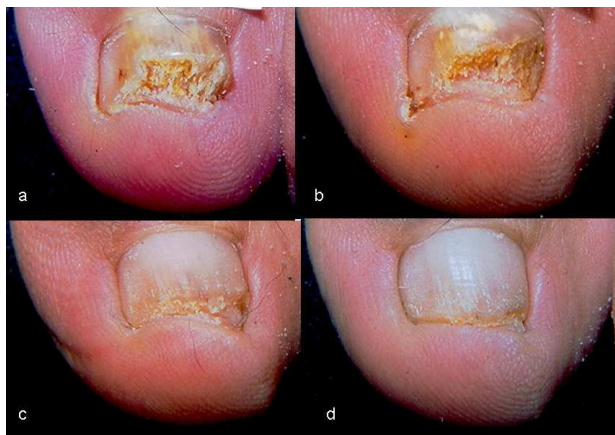

Figure 2. Example of treatment sequence

Discussion

The treatment of onychomycosis has changed as a result of the advent of new antifungal agents; however, this disease continues to be a problem for a certain proportion of them. It is common that after failure of oral therapy, patients try a different treatment; they may sometimes try topical therapy or switch to a different systemic therapy. In general and according with the meta-analysis studies, the best response to the oral treatment is obtained with terbinafine, which is superior to other oral antifungal agents [11-13]. There is thus an important number of patients who have failed the two most widely used drugs (itraconazole and terbinafine), even if given at the right dose and treatment duration. It is difficult to find the reason for the failure of both therapies, but some factors involved may be poor absorption of the drugs in the GI tract, patient non-compliance or probable fungal resistance to antifungals. The latter has not been proven and most *in vitro* studies only report the MIC ranges for the various dermatophytes [4,6,7].

This study stemmed from a publication by Gupta et al [12] that reported cases of chromoblastomycosis that responded poorly. Since we have had good results with this therapy, we decided to extrapolate it to cases of onychomycosis that did not respond to standard therapies. Even though the behavior of dermatophytes

differs from that of dematiaceous fungi such as *Fonsecaea pedrosoi*, we thought that both might share the same bases for the likely synergistic effect of these drugs.

The results of this study indicate that clinical and mycologic cure was obtained in 17/32 (53.12%) cases, meaning that more than half of the cases that had previously used both drugs were rescued. However, 15.6% of them only achieved clinical improvement and no mycologic cure, and approximately one third of the cases had no change. Concerning onychomycosis related to type 2 diabetes mellitus, 5 cases were included, 3 of which attained clinical and mycologic cure, indicating that most cases showed good treatment response. Nevertheless, we think that a specific study of patients with this condition who are refractory to the available treatments for onychomycosis is warranted to have a better idea of their response to this combination therapy. Considering the response as it relates to the clinical form, since most cases were DSO, they responded to treatment as well as 2/4 cases of TDO. This indicates that regardless of the clinical form of the disease, treatment response did occur in both types of onychomycosis [1,4,5].

A self-criticism of this study is that it should have been conducted together with an *in vitro* study to determine the initial MICs and compare them with the clinical treatment response.

Various *in vitro* studies, like the one by Santos & Hamdan,[13] show that the MIC for the two drugs with the best results against the dermatophytes *Trichophyton rubrum* and *Trichophyton mentagrophytes*, is 0.031-0.5 µg/ml for itraconazole and <0.031 µg/ml for terbinafine, and various authors think that the ranges of those MICs are appropriate for the treatment of onychomycosis. Although these results are similar to those of other studies, higher values are reported for some strains [14-16].

Although the cure rates with the weekly alternate therapy with itraconazole plus terbinafine are considered as low, it is important to stress the fact that those were salvage cases. The two-drug combination might have a synergistic effect, as happened in the treatment of chromoblastomycosis [12]. We did not find any *in vitro* studies in the literature indicating a synergistic effect of the two drugs, particularly against dermatophytes, particularly *Trichophyton rubrum*. However, a series of studies indicates that the combination of triazoles (fluconazole and itraconazole) + terbinafine may have a synergistic effect. For example, this combination has had a possible synergistic effect against *Candida albicans* strains that, in turn, has resulted in a decrease in the minimum inhibitory concentration for both triazoles [17,18]. Other studies indicate that the itraconazole + terbinafine combination may also have a synergistic action against *Aspergillus fumigatus* [19] and *Scedosporium prolificans* strains [20]. More recently, Gómez-López et al [21] also reported synergistic effects of this combination against several *Zygomycete* species. *In vitro* synergy was shown recently when terbinafine was combined with itraconazole and voriconazole against *Pythium insidiosum* strains [22]. In conclusion, there is a series of filamentous and yeast fungi in which a

direct and synergistic effect has been proven and this is probably what happens with dermatophytes as well [23]. The use of weekly alternate therapy with itraconazole and terbinafine is possible because both drugs have particular pharmacokinetic properties; both are depot drugs, especially at the stratum corneum level, so when given at the right doses they remain in the nails for long periods of time. More specifically, the plasma elimination half-life is 21 ± 5 hours for itraconazole 200mg [12,24] and 22 hours for terbinafine 250mg [25]. It is important to underscore that both drugs remain in plasma for short periods of time and they are deposited in the stratum corneum, where their concentration increases and thus allows them to act directly on dermatophytes.

It is important to emphasize that during the 4 months of treatment (two with itraconazole and two with terbinafine) no changes in laboratory test results occurred, especially in liver function tests, given that all patients remained within the normal ranges. Side effects occurred in two patients (6.25%); one had moderate headache and the other one mild loss of taste (dysgeusia). Both effects have been reported for both drugs and are considered as minor; treatment discontinuation was not necessary [5,7,24,26].

It is important to emphasize that this is a clinical-therapeutic report, and we consider it as a pilot study.

REFERENCES / PIŚMIENNICTWO:

1. André J, Achten G. Onychomycosis. *Int J Dermatol* 1987; 26:481-90
2. Baran R, Hay RJ, Tosti A, Haneke E. A new classification of onychomycosis. *Br J Dermatol* 1998; 139:567-71.
3. Gupta AK, Ryder JE, Summerbell RC. Onychomycosis: classification and diagnosis. *J Drugs Dermatol* 2004; 3:51-6.
4. Hay R. Literature review. Onychomycosis. *J Eur Acad Dermatol Venereol* 2005; 19 Suppl 1:1-7.
5. Jain S, Sehgal VN. Itraconazole versus terbinafine in the management of onychomycosis: an overview. *J Dermatolog Treat* 2003; 14:30-42.
6. Baran R, Gupta AK, Piérard GE. Pharmacotherapy of onychomycosis. *Expert Opin Pharmacother* 2005; 6:609-24
7. Thappa DM. Current treatment of onychomycosis. *Indian J Dermatol Venereol Leprol* 2007; 73:373-6.
8. Haugh M, Helou S, Boissel JP, Cribier BJ. Terbinafine in fungal infections of the nails: a meta-analysis of randomized clinical trials. *Br J Dermatol* 2002; 147:118-21.
9. Gupta AK, Ryder JE, Johnson AM. Cumulative meta-analysis of systemic antifungal agents for the treatment of onychomycosis. *Br J Dermatol* 2004; 150:537-44
10. Chang CH, Young-Xu Y, Kurth T, Orav JE, Chan AK. The safety of oral antifungal treatments for superficial dermatophytosis and onychomycosis: a meta-analysis. *Am J Med* 2007; 120:791-98.
11. Scher RK, Baran R. Onychomycosis in clinical practice: factors contributing to recurrence. *Br J Dermatol* 2003; 149 Suppl 65:5-9.
12. Gupta AK, Taborda PR, Sanzovo AD. Alternate week and combination itraconazole and terbinafine therapy for

Undoubtedly the critiques of this study consists of several points: In the future is necessary to have *in vitro* studies to value the MIC of the etiologic agents and to compare one or two control groups, as well as the possibility to make this a randomized trial, this will result in precise information about the effectiveness of the double therapy; the evaluation of the placebo percentage and a broad sample (n) will avoid to consider the results are owed at random. In our criteria, we continue considering the oral monotherapy as the first choice of treatment. It is important to highlight that this study would be statistically more accurate with a control group, however as the patients are refractory to therapies is difficult to create a control group using monotherapy, that is why conclusions are basically descriptive. Despite the small number of cases, this study shows that around half of the cases may be rescued and it is important to emphasize that we do not have new medications to offer to the onychomycosis refractory cases. In general, this study might be considered as a pilot or pioneer study, which brings a new hypothesis for future studies with randomized inclusion of cases.

- chromoblastomycosis caused by *Fonsecaea pedrosoi* in Brazil. *Med Mycol* 2002; 40:529-34
12. Gupta AK, Taborda PR, Sanzovo AD. Alternate week and combination itraconazole and terbinafine therapy for chromoblastomycosis caused by *Fonsecaea pedrosoi* in Brazil. *Med Mycol* 2002; 40:529-34
13. Santos DA, Hamdan JS. In vitro antifungal oral drug and drug-combination activity against onychomycosis causative dermatophytes. *Med Mycol* 2006; 44:357-62.
14. Bradley MC, Leidich S, Isham N, Elewski BE, Ghannoum MA. Antifungal susceptibilities and genetic relatedness of serial *Trichophyton rubrum* isolates from patients with onychomycosis of the toenail. *Mycoses* 1999; 42 Suppl 2:105-10.
15. da Silva Barros ME, de Assis Santos D, Hamdan JS. Evaluation of susceptibility of *Trichophyton mentagrophytes* and *Trichophyton rubrum* clinical isolates to antifungal drugs using a modified CLSI microdilution method (M38-A). *J Med Microbiol* 2007; 56(Pt 4):514-8.
16. Sarifakioglu E, Seçkin D, Demirbilek M, Can F. In vitro antifungal susceptibility patterns of dermatophyte strains causing tinea unguium. *Clin Exp Dermatol* 2007; 32:675-9.
17. Barchiesi F, Di Francesco LF, Compagnucci P, Arzeni D, Giacometti A, Scalise G. In-vitro interaction of terbinafine with amphotericin B, fluconazole and itraconazole against clinical isolates of *Candida albicans*. *J Antimicrob Chemother* 1998; 41:59-65.
18. Ryder NS, Wagner S, Leitner I. In vitro activities of terbinafine against cutaneous isolates of *Candida albicans* and other pathogenic yeasts. *Antimicrob Agents Chemother* 1998; 42:1057-61
19. Ryder NS, Leitner I. Synergistic interaction of terbinafine with triazoles or amphotericin B against *Aspergillus* species. *Med Mycol* 2001; 39:91-5.

20. Meletiadis J, Mouton JW, Rodriguez-Tudela JL, Meis JF, Verweij PE. In vitro interaction of terbinafine with itraconazole against clinical isolates of *Scedosporium prolificans*. *Antimicrob Agents Chemother* 2000; 44:470-2.
21. Gómez-López A, Cuenca-Estrella M, Mellado E, Rodríguez-Tudela JL. In vitro evaluation of combination of terbinafine with itraconazole or amphotericin B against Zygomycota. *Diagn Microbiol Infect Dis* 2003; 45:199-202.
22. Argenta JS, Santurio JM, Alves SH, Pereira DI, Cavalheiro AS, Spanamberg A, Ferreiro L. In vitro activities of voriconazole, itraconazole, and terbinafine alone or in combination against *Pythium insidiosum* isolates from Brazil. *Antimicrob Agents Chemother* 2008; 52:767-9.
23. Revankar SG, Nailor MD, Sobel JD. Use of terbinafine in rare and refractory mycoses. *Future Microbiol* 2008; 3:9-17.
24. Caputo R. Itraconazole (Sporanox) in superficial and systemic fungal infections. *Expert Rev Anti Infect Ther* 2003; 1:531-42.
25. Jensen JC. Clinical pharmacokinetics of terbinafine (Lamisil). *Clin Exp Dermatol* 1989; 14:110-3.